

USE OF OZOILE IN TREATMENT OF LESIONS WITH MIXED ETIOLOGY



Dott. Cosimo Maglio[≈], Inf. Esp. Wound Care Monica Gonnelli*

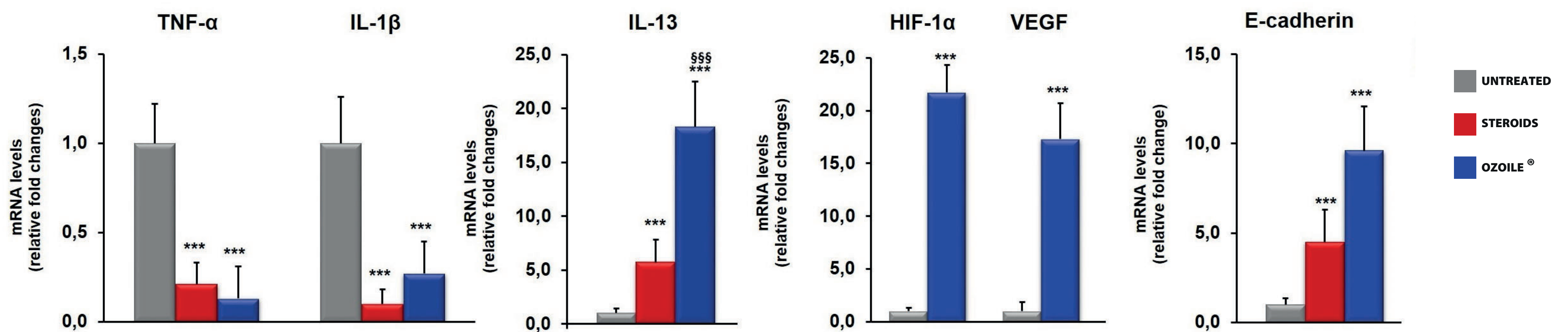
[≈] U.O.C. Chirurgia Generale, Responsabile Sezione Semplice di Vulnologia,

* Sezione Semplice di Vulnologia, - [≈]* Ambulatorio di Vulnologia, - [≈]* Azienda USL Toscana Sud Est, Italia



BACKGROUND AND AIMS

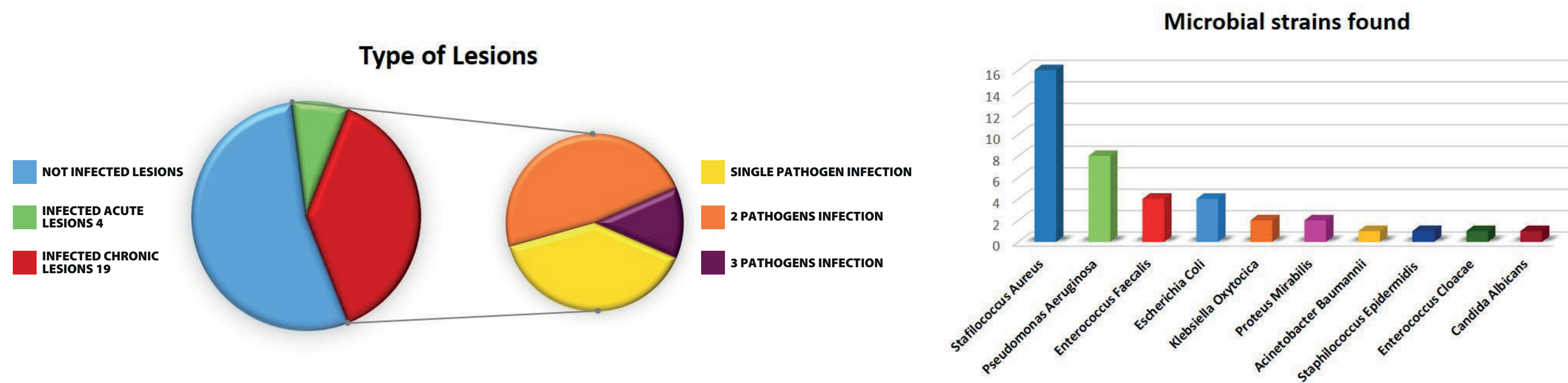
Skin lesions characterized by different etiopathogenesis are often chronic and associated with various diseases (> elderly patients). Chronic skin ulcers affect about 80 million people, in Italy more than 2 million (0.4% of admissions and 1% of all days in hospital). Home-Healthcare Management is an optimal treatment, with a reduction in healthcare costs, with a faster recovery and improvement in the quality of life of patients. The aim of the work is to verify clinically the anti-inflammatory, antimicrobial and tissue regeneration action by the use of Ozoile® (Stable Ozonides with Vitamin E acetate) [1] [2].



METHODS

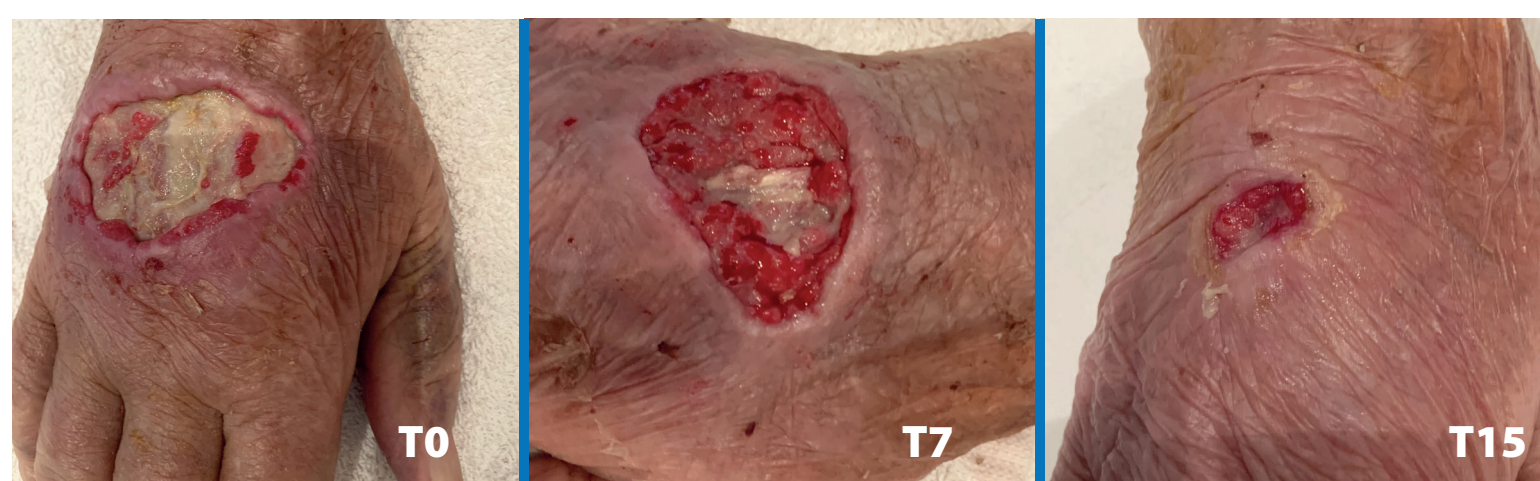50 patients (32 F, 18 M); average age 65.5 (range 42-90); 13 acute and 37 chronic lesions; diameter < 30 cm²; 23 infected lesions (4 acute, 19 chronic); 14 polymicrobial infections; 10 microbial strains. Pain assessment based on VAS.

For each patient: history, ecocolordoppler, VAS, swab Culture; medication by Ozoile® *, Reassessment after 7, 15, 30, 60 days with photos, VAS, swab Culture.

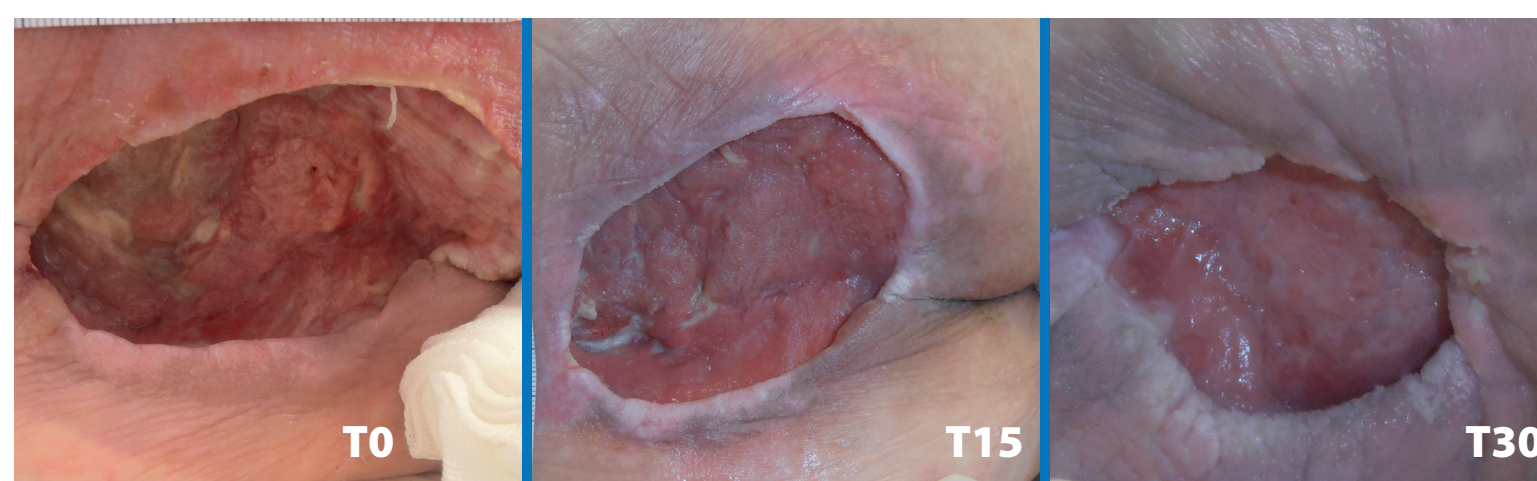


RESULTS

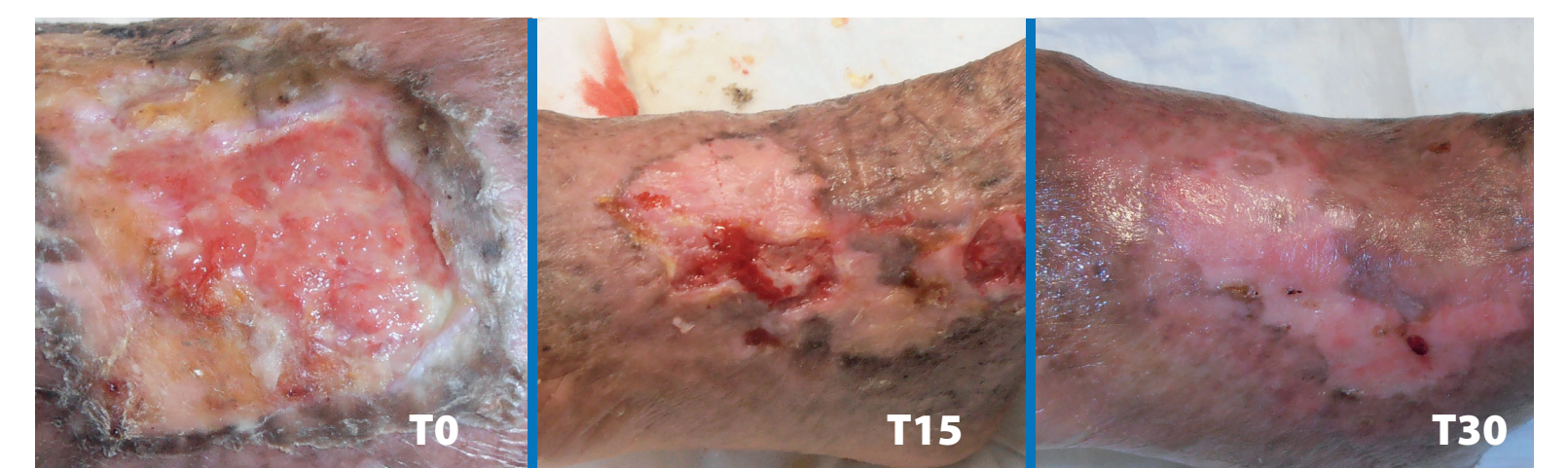Reduction in lesion diameter in all patients; complete healing (90%); reduction of VAS; reduction of inflammation parameters, microbicidal action, good trophism of regenerated skin.



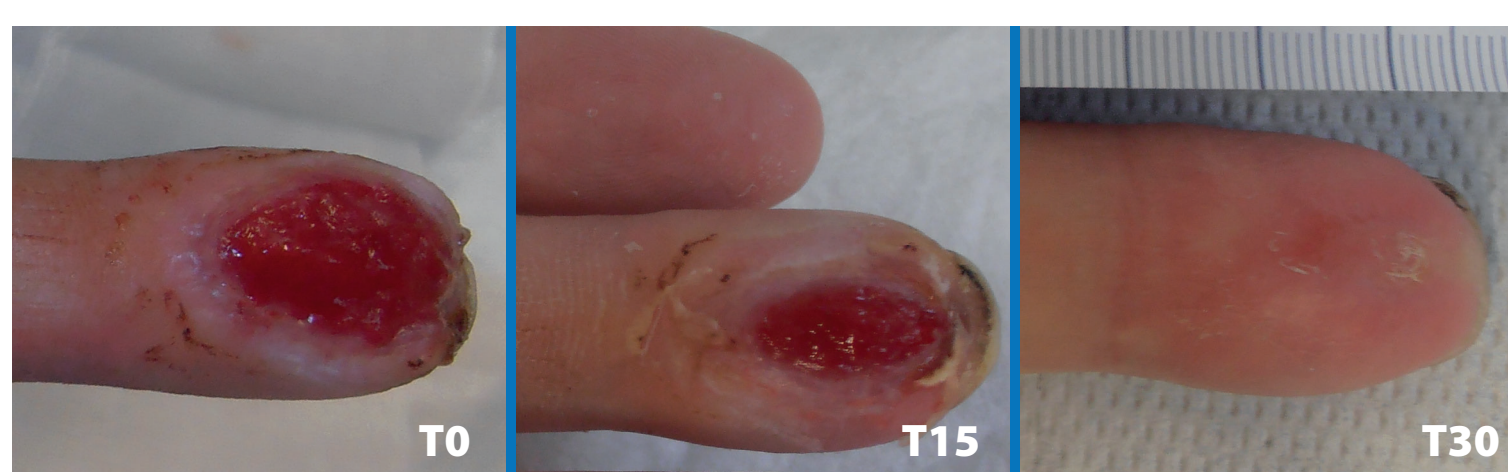BLUNT TRAUMA WITH LOSS OF SUBSTANCE



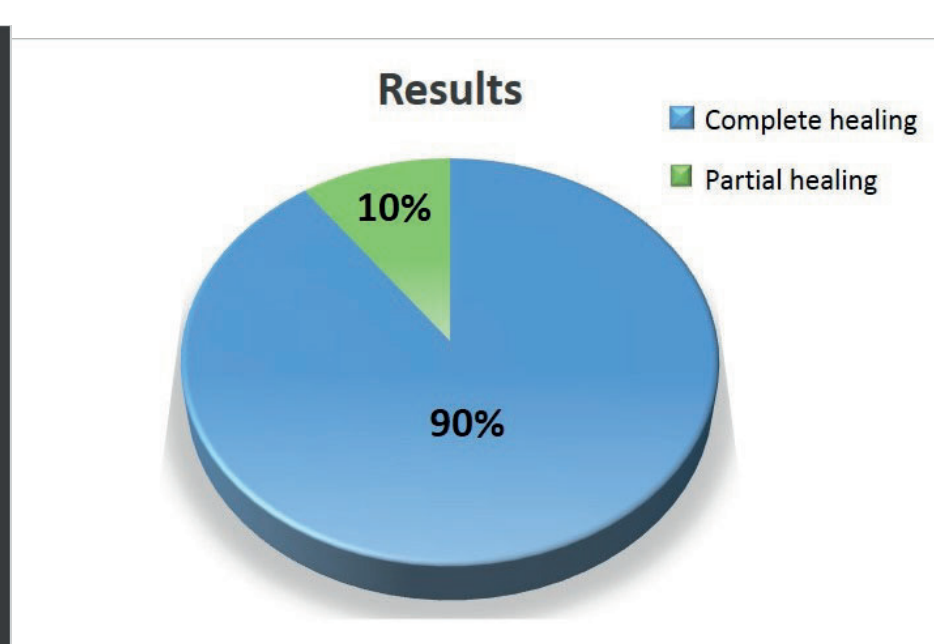
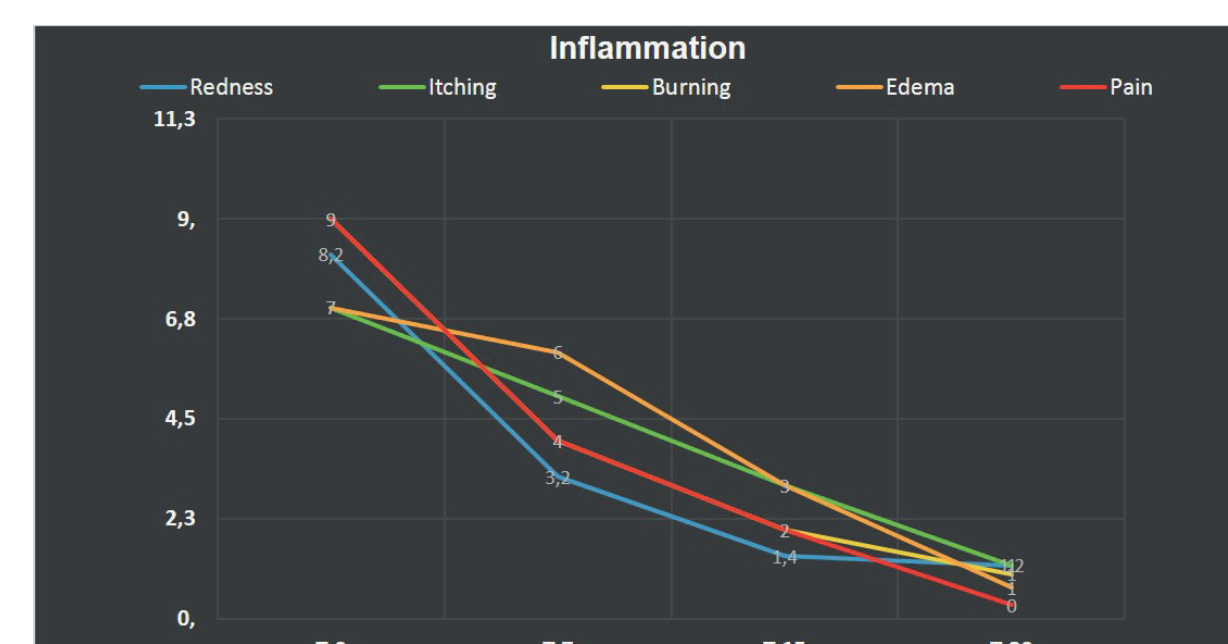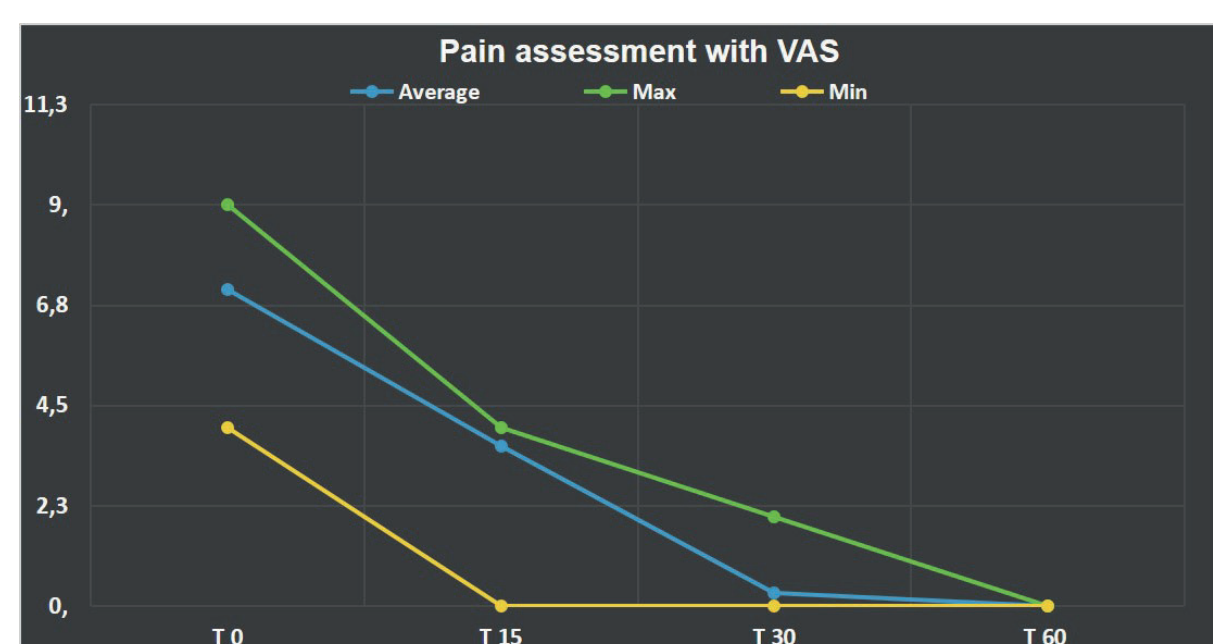
PRESSURE ULCER IN SACRAL REGION



VENOUS LEG ULCER



CRUSH TRAUMA WITH LOSS OF SUBSTANCE



CONCLUSIONS

The treatment of skin lesions is important in order to improve the quality of healthcare system to reduce the healthcare costs and to improve the quality of life of patients.

The use of Ozoile® can be useful in the Home-Healthcare Treatment of acute and chronic skin lesions characterized by different etiologies. Ozoile® Home-Healthcare Treatment shows an evident reduction in the ulcers diameter, shorter healing times, lower accesses in clinic and reduction of antibiotic and cortisone therapy, reduction in healthcare costs, a good cost/benefit ratio and best results in the tissue regeneration.

* Rigenoma® spray - cream - gauze (Erbagil Italy)

BIBLIOGRAPHY

- 1- Tiziana Russo, Monica Currò, Nadia Ferlazzo, Daniela Caccamo, Patrizia Perrone, Salvatore Arena, Enrica Antonelli, Pietro Antonuccio, Riccardo Ientile, Carmelo Romeo, Pietro Impellizzeri, Stable Ozonides with Vitamin E Acetate versus Corticosteroid in the Treatment of Lichen Sclerosus in Foreskin: Evaluation of Effects on Inflammation, Urol Int, April 16 2019
- 2- Monica Currò, Tiziana Russo, Nadia Ferlazzo, Daniela Caccamo, Pietro Antonuccio, Salvatore Arena, Saveria Parisi, Patrizia Perrone, Riccardo Ientile, Carmelo Romeo and Pietro Impellizzeri, Anti-Inflammatory and Tissue Regenerative Effects of Topical Treatment with Ozonated Olive Oil/Vitamin E Acetate in Balanitis Xerotica Obliterans Molecules 2018, 23,645, 13 Marzo 2018.